

# 10 years follow up after prenatal transplantation of fetal MSC in a patient with severe osteogenesis imperfecta

P1

Cecilia Götherström,<sup>1,2</sup> Katarina Le Blanc,<sup>1,3</sup> Eva Åström,<sup>4</sup> Jahan Taslimi,<sup>5</sup> Gail E. Graham,<sup>6</sup> Uwe Ewald<sup>6</sup> & Magnus Westgren<sup>1,7</sup>

<sup>1</sup>Division for Obstetrics and Gynecology, <sup>2</sup>Center for Hematology and Regenerative Medicine, <sup>3</sup>Hematology Center, <sup>4</sup>Department of Woman and Child Health and Neuro-pediatric Unit, <sup>5</sup>Center for Fetal Medicine, Karolinska Institutet and Karolinska University Hospital, Stockholm, Sweden. <sup>6</sup>Orthopedic Unit, Uppsala University Hospital, Uppsala, Sweden. <sup>7</sup>Department of Genetics, Children's Hospital of Eastern Ontario and Department of Pediatrics, University of Ottawa, Ottawa, Canada. <sup>8</sup>Women's and Children's Health, Uppsala University, Uppsala, Sweden.

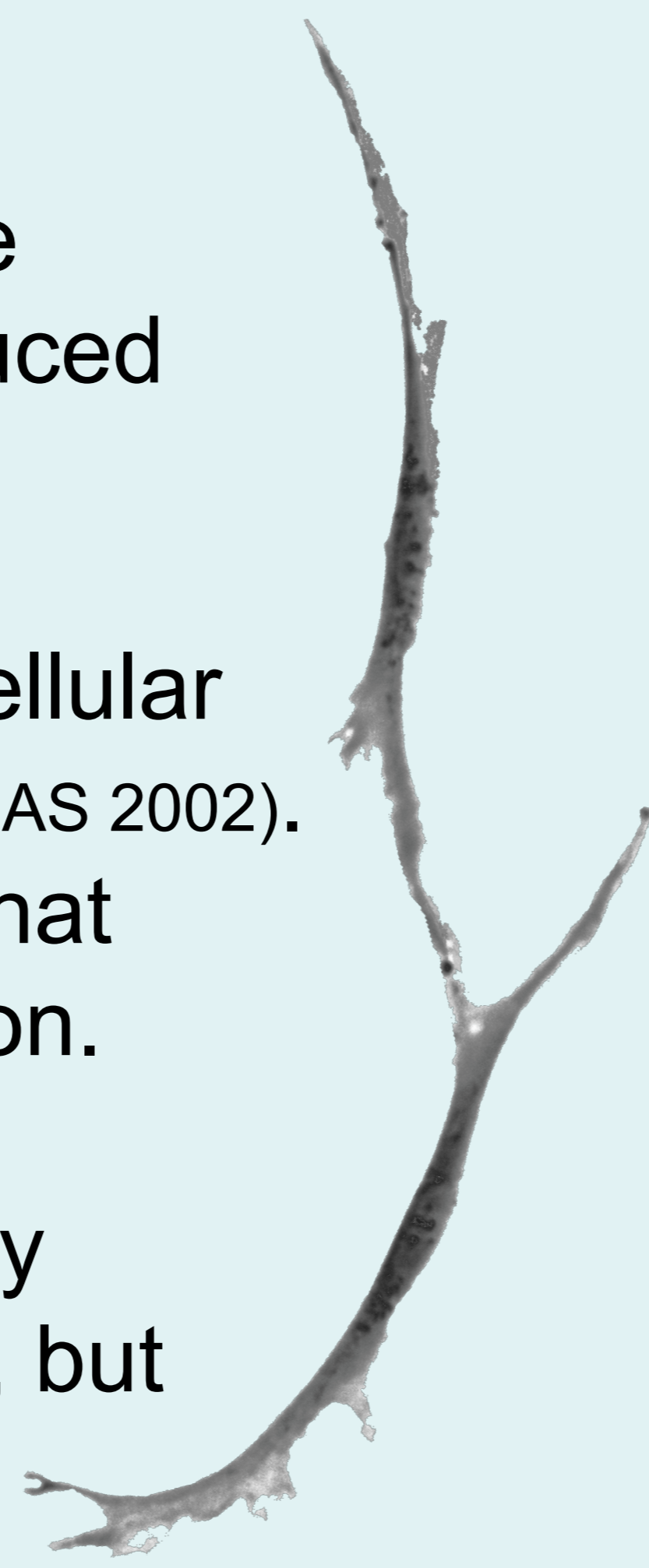
## Introduction

Treatment with multipotent mesenchymal stromal cells (MSC) has the potential to ameliorate mesodermal disorders, including bone.

Osteogenesis imperfecta (OI) is a genetic bone disorder leading to repeated fractures and reduced height.

Adult HLA-matched MSC have been used in cellular therapies of OI with promising results (Horwitz, PNAS 2002). MSC are regarded as immunoprivileged cells that could support allogeneic prenatal transplantation.

Prenatal transplantations have been successfully performed in children with immunodeficiencies, but has so failed in immunocompetent recipients.



## Conclusions

Our findings suggest that transplantation of allogeneic fetal MSC in OI is safe and re-transplantation postnatally with same-donor cells is possible.

Fetal MSC can be transplanted across HLA barriers and undergo site-specific differentiation to bone.

Although caution is needed, it seems that the longitudinal growth and fracture incidence has increased after the re-transplantation.

It is not possible from this single case to conclude on beneficial effects of MSC in OI, but an infant with identical mutation (personal communication) who did not receive MSC treatment succumbed at 5 months of age despite postnatal bisphosphonate therapy.

## The patient & Transplantation

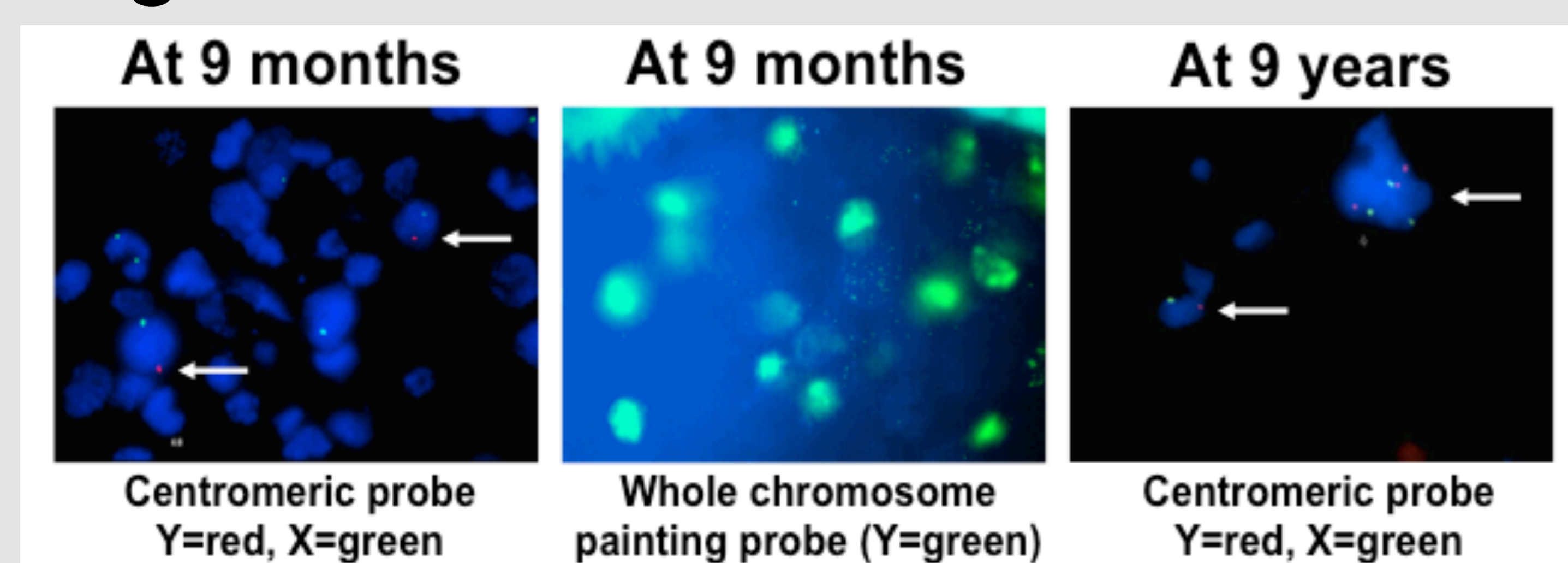
The patient was diagnosed with OI type III prenatally due to multiple fractures and typical signs of severe OI. Mutation: *de novo* COL1A2: c.3008G>A, p.Gly1003Asp, Gly913Asp in the triple helix (Le Blanc, Transplantation 2005).

She was transplanted prenatally with  $6.5 \times 10^6$  fully HLA mis-matched male fetal MSC in week 32 of gestation and born after cesarean section in week 36.

At 8 years of age she was re-transplanted with  $2.8 \times 10^6$  kg same-donor MSC 5 days after a correctional surgery bilateral femoral osteotomy and replacement of rods.

She has been treated with bisphosphonates (i.v. Pamidronate) since 4 months of age.

## Engraftment of donor cells



FISH analysis was performed on bone at 9 months, 6 and 9 years. Y-chromosome positive cells were detected at 9 months and 9 years as indicated by arrows. Donor cells were only detected in bone.

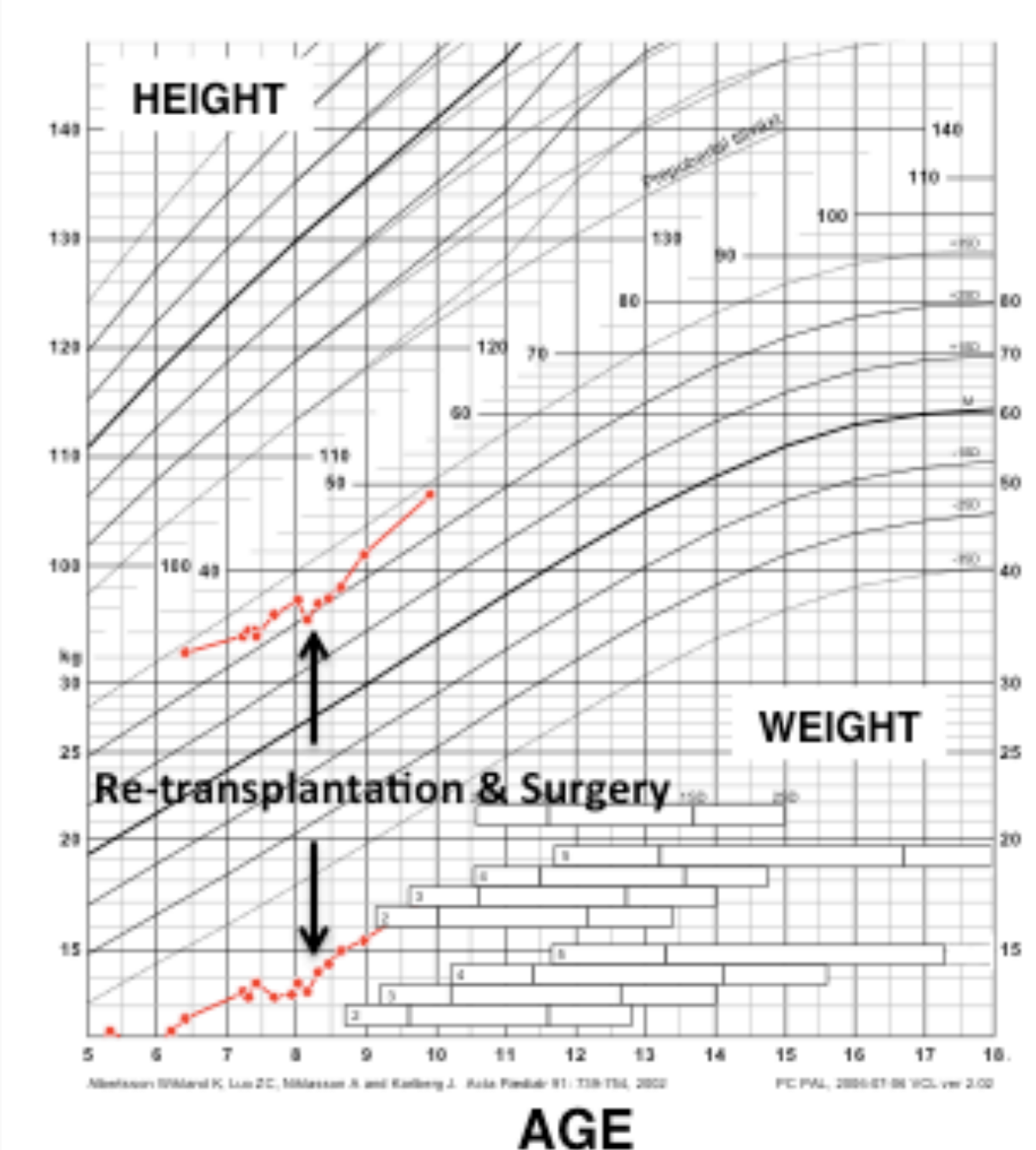
- 9 months centromeric: 17 Y-chromosome positive cells/2,500 cells.
- 9 months whole chromosome painting: 228 Y-chromosome positive cells/2,500 cells.
- 9 years (6 months post re-transplantation): 4 Y-chromosome positive cells/60,000 cells.

## Immunological reaction

The patient has no lymphocyte reaction against donor MSC (figures to the right) or antibodies against donor HLA I or II, IgG or IgM or fetal calf serum (not shown).

## Growth

After re-transplantation and surgery, her linear growth has improved from -6.5 to -6 SD and she is following her own growth curve.



## Fracture incidence

At 10 years of age, 12 postnatal fractures and 11 vertebral compression fractures have been confirmed.

4 fractures and 1 vertebral compression fracture have been clinically suspected.

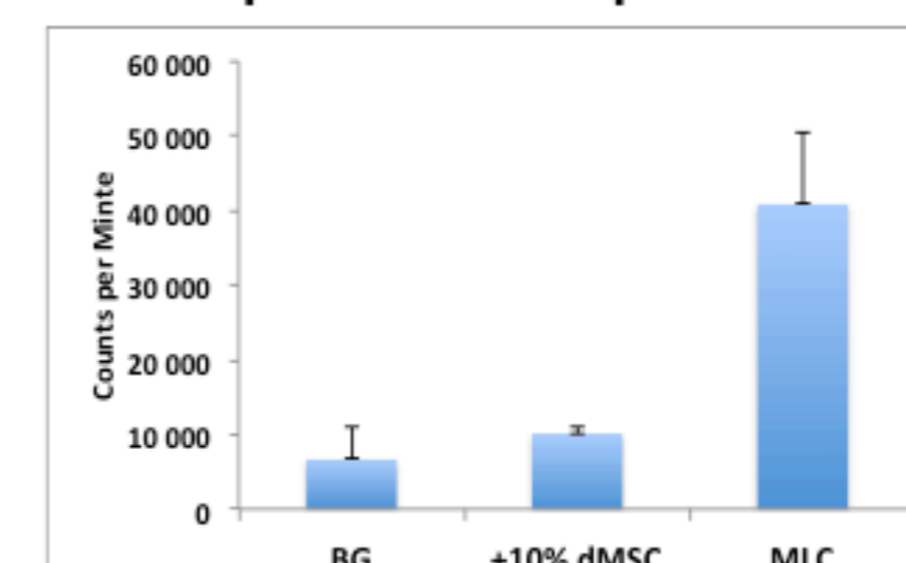
No fractures for 2 years after re-transplantation.

She has developed a scoliosis treated with a brace since 6 years of age.

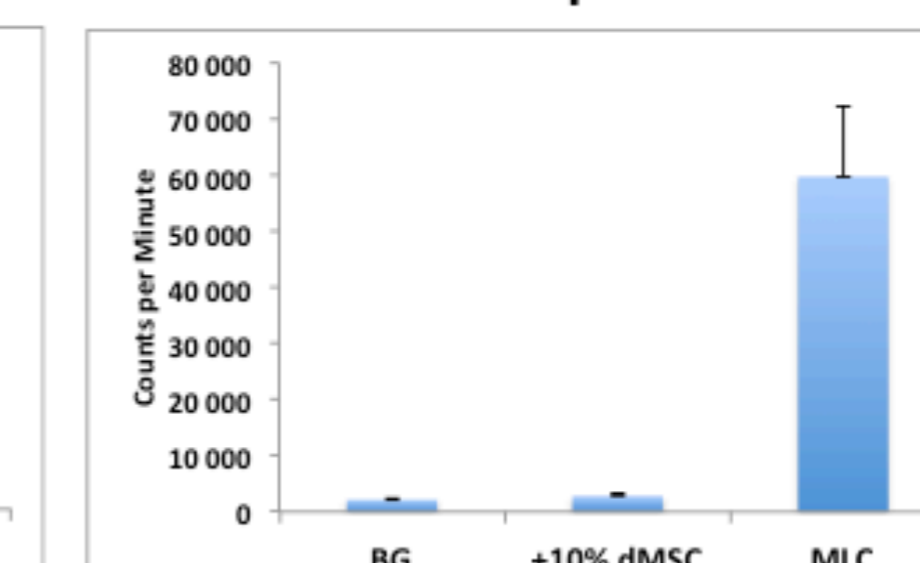
## Clinical course

At present, the patient is 10 years old and is doing better than expected. Her ability to walk has improved (can walk 1000 meters) and she takes dance classes and participates in modified indoor hockey.

### Pre prenatal transplantation



### Pre re-transplantation



Mixed lymphocyte culture to detect any patient reaction towards the donor cells before prenatal transplantation and before re-transplantation at 8 years

of age. The patient has never demonstrated an immunological reaction towards the donor MSC (dMSC) or presence of antibodies directed towards HLA class I and II, IgG and IgM or FBS. BG=Background. For methodological details see Le Blanc, Transplantation 2005.